

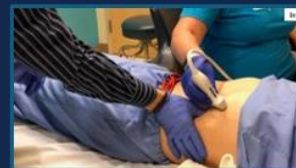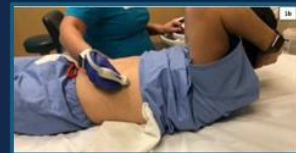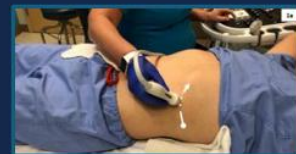Original Property of Phoenix Children's Hospital.

This information is intended only for education and protocol development, etc. The authorized recipient is prohibited from disclosing this information as their own work. If you are not the intended recipient, you are hereby notified that any disclosure, copying, distribution, or action taken in reliance on the contents of this document is strictly prohibited. If you received this in error, please notify the sender immediately to arrange for return.



Study Design and Protocol

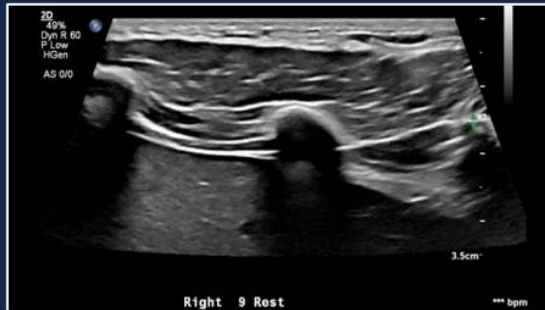
- Scanning techniques for assessment of SRS:
 - Morphology (1a)
 - Crunch maneuver (1b)
 - Push maneuver (1c)
 - *Cineclips are obtained for each maneuver*



Study Design and Protocol

MORPHOLOGY / AT REST

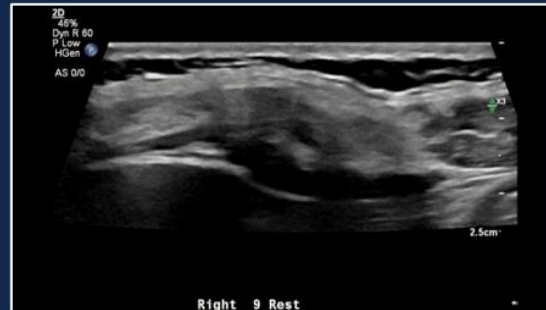
Normal



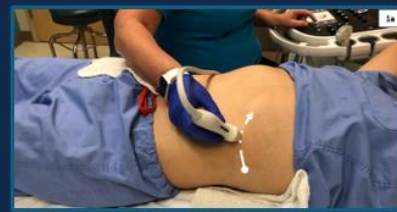Normal (negative) at-rest costal morphology



Abnormal



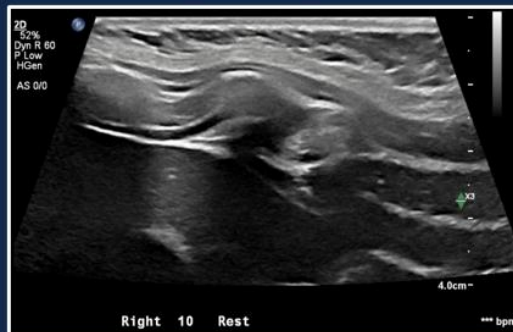
Abnormal (positive) at-rest costal morphology



Study Design and Protocol

MORPHOLOGY / AT RISK

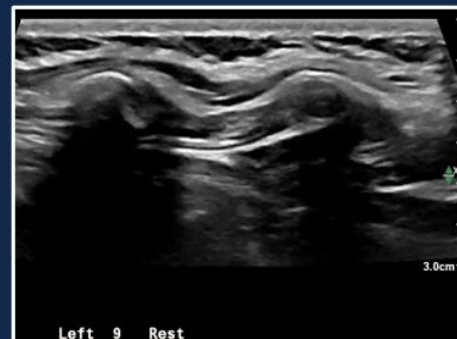
Close proximity



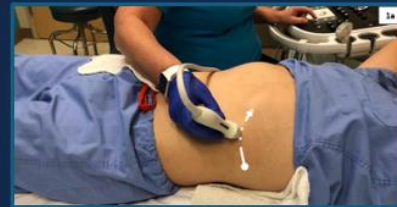Questionable at-rest costal morphology



Bar



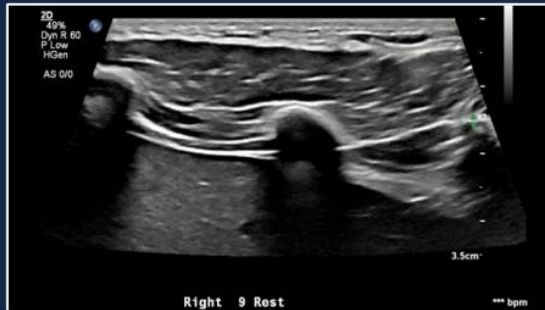
Questionable at-rest costal morphology



Study Design and Protocol

MORPHOLOGY / AT REST

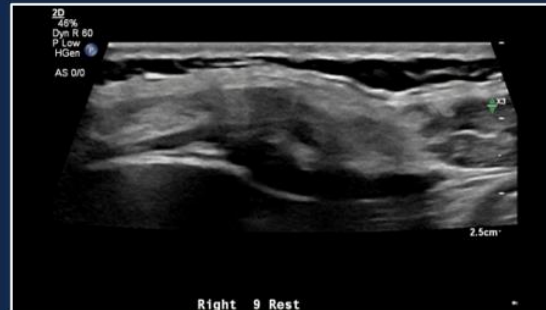
Normal



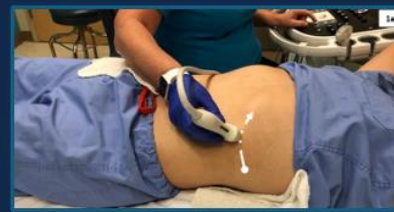Normal (negative) at-rest costal morphology



Abnormal



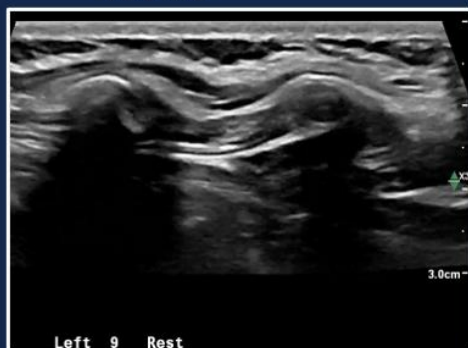
Abnormal (positive) at-rest costal morphology



Study Design and Protocol

MORPHOLOGY / AT RISK

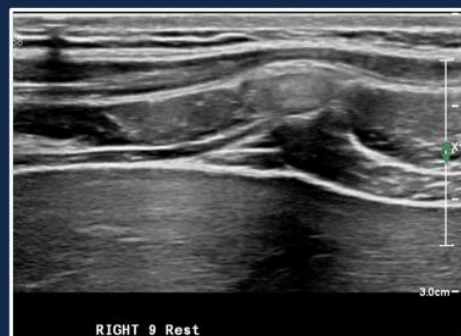Hooked



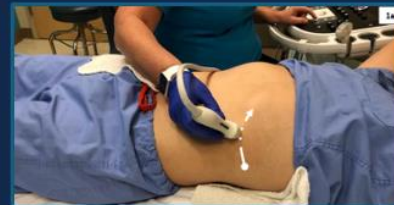Questionable at-rest costal morphology



Increased Echogenicity



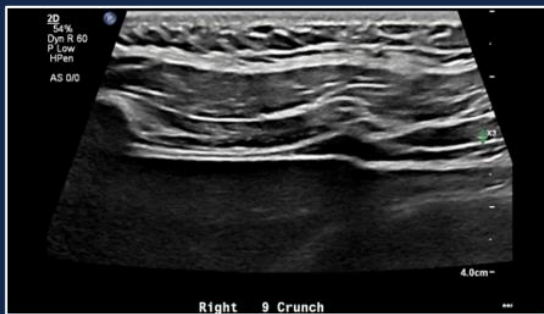Questionable at-rest costal morphology



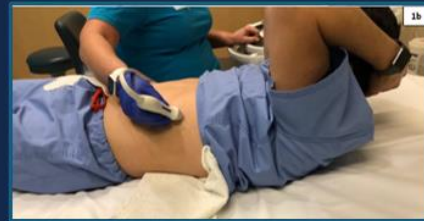Study Design and Protocol

CRUNCH MANEUVER

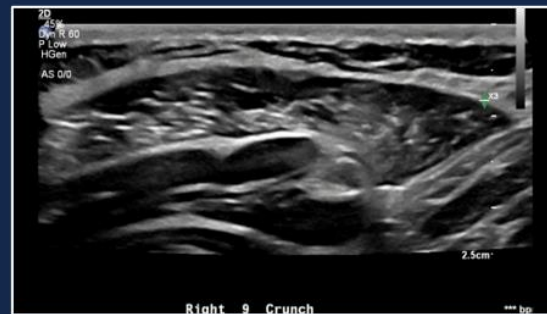Normal



Normal (negative) motion during the crunch maneuver.



Abnormal

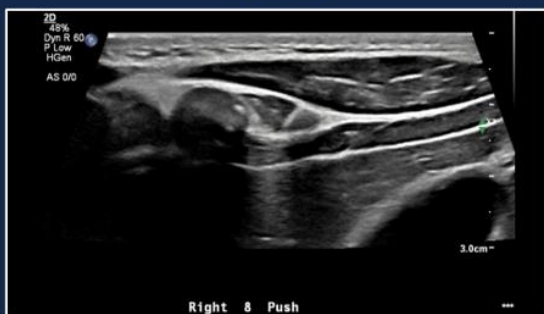


Abnormal (positive) motion during the crunch maneuver.

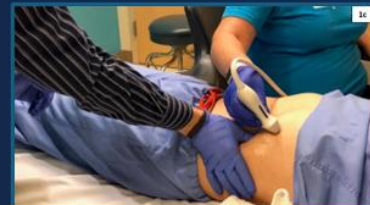Study Design and Protocol

PUSH MANEUVER

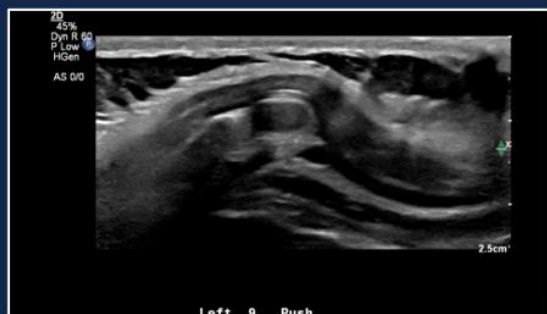Normal



Normal (negative) motion during the push maneuver



Abnormal



Abnormal (positive) motion during the push maneuver